

Copyright © 1966, by the author(s).
All rights reserved.

Permission to make digital or hard copies of all or part of this work for personal or classroom use is granted without fee provided that copies are not made or distributed for profit or commercial advantage and that copies bear this notice and the full citation on the first page. To copy otherwise, to republish, to post on servers or to redistribute to lists, requires prior specific permission.

SKIN NECROSIS

by

John Sills

Memorandum No. ERL-M142

7 April 1966

ELECTRONICS RESEARCH LABORATORY

College of Engineering
University of California, Berkeley
94720

Manuscript submitted: 15 December 1966

ACKNOWLEDGMENTS

I should like to take this opportunity to thank Professors P. O. Vogelhut and C. Susskind for arranging for me to work on this problem and for their interest in the work; Miss Karen Howard for her technical assistance and tolerance; and Mr. W. C. Berger of the U. C. Lawrence Radiation Laboratory for the use of one of his rabbits, his laboratory, and his facilities.

This work was supported by U.S. P.H.S. Bioengineering Training Grant G7-1418, which provided the funds for summer employment of the author.

SUMMARY

Possible causes of severe skin necrosis in a 13-month-old male infant who had undergone an EEG test were investigated in various ways. Spot pin-prick tests on human skin showed that solutions of CaCl_2 were more irritating than other solutions of Ca salts. Subcutaneous injections into a rabbit of a wide range of solutions of different concentrations demonstrated that both calcium chloride and silver nitrate caused necrosis. The two lesions were, however, different in character and in their relation to concentration. The significance of these findings is discussed in relation to the original case and to some similar lesions reported elsewhere.

INTRODUCTION

Colonel R. B. Giffin of the U. S. Army Medical Corps has brought to our attention a medical incident that could have been possibly traced to interception of microwave radiation of high intensity, though that hypothesis has been viewed with considerable skepticism from the first. Severe scalp necrosis occurred shortly after a routine encephalogram of a 13-month-old male infant was taken at a laboratory adjoining military and civilian airfields and frequently overflowed by aircraft carrying radar equipment. The necrosis occurred at the sites of the frontal electrodes, the only sites without scalp hair. The necrotic areas appeared to be identical with the areas covered by the paste in which the electrodes were embedded. The electrodes were small disks of metallic silver about 1 cm in diameter. The necrotic areas became hard eschars and after about one month separated from the underlying granulation tissue that had developed in response to the injury.

The possible causes of the necrosis considered were sensitivity to bentonite paste, simple electrical burn, damage from radio-frequency currents, and iontophoresis of silver. Patch testing the infant with the paste had produced a negative result. This finding would appear to confirm theoretical considerations, which (from the time-course and character of the lesions) predict a negative result. Thus an immunological etiology may be excluded. Direct-pressure necrosis and

electrical burn were also ruled out. Radio-frequency currents were considered a possible but unlikely source of necrosis. The most likely cause of this localized and unique tissue damage was considered to be iontophoresis of silver ions into the epidermis.

Other authorities consulted have considered that the necrosis might be related to other ions in the system, e. g., calcium, sodium, or chloride ions, or even perhaps the bentonite or glycerine. The present paper describes a series of experiments designed to test the effects of such ions in various systems.

Evaluation of Cutaneous Irritative Properties

Solutions of the several ions were tested on the skin of the anterior aspect of the forearm. Two subjects were used; the writer and a volunteer (X) from this Laboratory.

After cleaning of the skin with ethyl alcohol, two separate drops of the test solution were placed on the skin, which was then lightly pricked with a sterile stylet. Five minutes later the skin was wiped clean. Any response usually became visible within 10 minutes. Erythema, reddening of the skin due to vasodilation of the blood vessels in the area around the prick site, is the first manifestation and may be followed by the formation of a wheal, a skin bleb caused by increased capillary permeability and exudation of serum. This secondary whealing was in fact only seen with the stronger histamine solutions and with hydrochloric acid. The comparison between the solutions was made by measuring the diameter of the erythema. This method is subject to

inaccuracies insofar as the dose introduced into the skin cannot be controlled particularly well, but nevertheless some tentative conclusions are drawn from the results obtained.

To facilitate the differentiation between the effects owing to the separate Ca^{++} , Na^+ , and Cl^- ions, solutions of calcium gluconate (CaGlu) were used as alternate sources of Ca^{++} ions. The results are shown in Table 1.

Table 1. --Results of pin-prick tests on human forearms.

(1)	Histamine: 1/200, whealing, erythema, diam 6 mm
	1/400, " " " 4 mm
	1/800, " " " 2 mm
	1/1600, " " " ca 1.5 mm
	Calcium chloride: 10% no whealing, erythema diam 3 mm
	Saturated solu. no whealing; erythema diam ca 2.5 mm
	Sodium chloride: 10%, no whealing; erythema diam 5 mm (the two areas were confluent)
	Saturated, no whealing; erythema diam ca 2 mm
	Calcium gluconate: 10%, no whealing; erythema diam 3 mm
	Sodium hydroxide: 4%, no whealing; erythema diam 3 mm
	Hydrochloric acid: 3.75%, whealing, erythema diam 4 mm
	Distilled water: small marks on the skin indicating the pin pricks.
(2)	CaCl ₂ NaCl CaGlu Glycerine H ₂ O
	15 - - 5 - Erythema; diam 4.5 mm
	15 - - 5 10 " " 4.5 mm
	- 10 - 5 15 " " 2.5 mm
	- 10 15 5 - " " 2.5 mm
	- - 15 5 10 " " 1.5 mm

From experiment (1) it appears that calcium, sodium, and chloride ions can all produce erythema without whealing. However, in the second series the response was greater when CaCl_2 was present. The $\text{CaCl}_2/\text{NaCl}$ and CaCl_2 solutions produced the strongest reactions, the NaCl solution was the next most irritating, and the CaGlu/NaCl solution was about the same. CaGlu alone was less irritating than any

other. Thus there appears to be a significant difference between CaCl_2 and CaGlu , and the active ion seems to be the chloride ion. However, studies of the pH values of the various solutions used (as shown in Table 2) indicate that the pH of the CaCl_2 solution (8.08) is higher than that of the CaGlu solution (6.62), so that the different responses might be related to the pH rather than to the specific ions present.

Silver nitrate solutions at concentrations of 1 and 2% were also tested. They produced a transient erythema of small (2-mm) diameter which like all the reactions resolved in about 1.5 hr. However, the skin later developed a brown pigmentation in the areas of the test, which turned to black specks in two days. This result was presumably caused by precipitation of silver (as the chloride) subcutaneously. No ulceration or necrotic action was observed.

Tests with Bentonite Pastes

During an electroencephalogram, bentonite paste is applied to the skin and the electrodes are pressed into the paste. This paste contains the following substances:

Bentonite 75 parts
Calcium chloride (saturated) 15 parts
Sodium chloride (saturated) 10 parts
Glycerine 5 parts

Electrodes of metallic silver are also present. To test the effects of these substances on skin, pastes were made up of compositions shown in Table 3.

Table 2. --pH values of the solutions used.

CaCl ₂	NaCl	H ₂ O	Glycerine	CaGlu	pH
15	10	-	-	-	8.13
15	10		5	-	7.90*
15	-	10	-	-	8.26
15	-	10	5	-	8.08*
-	10	15	-	-	6.98
-	10	15	5	-	6.20*
-	-	25	-	-	6.35
-	-	25	5	-	5.68
-	10	-	-	15	6.36
-	10		5	15	6.42*
-	-	10	-	15	6.62
-	-	10	5	15	6.62*

AgNO₃ (saturated) pH: 8.75.

These pH values are of solutions which, when mixed with bentonite in the proper proportions, produced pastes similar to those used in the encephalogram. Some of the solutions, marked by asterisks in the table above, were also used in the cutaneous pin-prick tests.

No lesions of any description were observed. Indeed, the only action of the paste was seen where the AgNO_3 containing paste had been

Silver nitrate was added in an attempt to simulate the postulated iontophoresis of silver. In fact, the silver precipitated (as the chloride) when it was added to the paste.

The samples of paste were applied to the shaven flank of a male albino rabbit and were left in position for 1.5 hr, more than the length of time during which the patient has been in contact with the paste, since it was hoped that by increasing the contact time any small response to the paste would be enhanced.

* These paste samples were supplied by Dr. Giffin and were used to compare the effects of the made-up and the standard pastes.

	Bentonite	CaCl_2	NaCl	CaCl_2	H_2O	Glycerine
1) *	75	15	10	-	-	5
2) *	75	15	10	-	-	5 (+0.1 ml AgNO_3)
3)	75	15	10	-	-	5
4)	75	15	10	-	-	5 (+0.1 ml AgNO_3)
5)	75	15	-	-	10	5
6)	75	-	10	-	15	5
7)	75	-	10	15	-	5
8)	75	-	-	15	10	5
9)	75	-	-	-	25	5
10)	75	15	10	-	-	

Table 3. --Bentonite-paste compositions tested.

in contact with the skin. Here the skin darkened, probably because of the deposition of metallic silver reduced from the precipitated silver chloride in the paste. During the following 10 days, no lesion of any kind developed.

Thus, the skin of this rabbit appeared to be insensitive to the various pastes. As in the cutaneous tests, it was hoped that by using calcium gluconate, the Cl^- ion could be differentiated from the Ca^{++} ion. From the pH values of the solutions used in the pastes (Table 2) it will be seen that in this experiment the pH appears to have no effect on the response. Because of technical difficulties, the effect on the pH of including the solution with the clay was not studied. It is possible that the clay may have a buffering action, thereby reducing the high pH of the $\text{CaCl}_2/\text{NaCl}$ solutions.

Studies of the Effects of Subcutaneous Injections of Solutions of Salts

To determine whether it was possible to produce local necrosis by the substances present in the electrode paste system, a series of solutions of salts was prepared. Aliquots of 0.1 ml were injected subcutaneously into the shaven flank skin of the same rabbit.

The following solutions were injected:

CaCl_2	Saturated solution.	Result: necrosis (++++)
	10%	(++++)
	5%	(+++)
	1%	no necrosis

NaCl Saturated solution.	Result: no necrosis
10%	no necrosis
5%	no necrosis
1%	no necrosis

CaGlu Saturated solution.	Result: necrosis (+++++)
10%	no necrosis
5%	no necrosis
1%	no necrosis

AgNO ₃ 1%	Result: necrosis (+++)
----------------------	------------------------

The lesions caused by the solutions of CaCl₂ showed the following developmental sequence. After injection the areas turned blue, developed a pale center (2-3 mm) surrounded by a purple-black ring (1-2 mm) and rimmed by erythema. This general pattern was maintained for 4-5 days but the lesions raised up, hair growth was halted, and the color of the lesions darkened. After about a week the lesions were raised disks of hard, scab-like necrotic tissue. The extent of the lesions appeared to be related to the concentration of the salt: the saturated and the 10% lesions were more severe than the 5% lesions, and the 1% solution produced no necrosis.

Solutions of CaGlu produced no necrosis at concentrations of 10, 5, and 1%. However, the saturated solutions produced lesions similar to those of CaCl₂. At the end of a week, the lesions were large raised necrotic disks with dark depressed centers. The diameter of the lesions was 1.5 cm.

Solutions of NaCl produced no necrosis.

At the sites of AgNO₃ injection, small lesions were produced. Soon after injection, the injection site appeared dark brown, owing to the precipitation of silver. The brown area became surrounded by a pale white ring tinged with erythema. Unlike the CaCl₂ lesions, the necrosis did not extend but remained localized within an area of 3 mm diameter. Later the area became raised, but the scab was small and had no depressible center.

Some of the above results are shown in Fig. 1.

The raising of the lesions was probably caused by the formation of subjacent granulation tissue, as could be doubtless confirmed by microscopic histological studies on samples of the lesions, but time and facilities were lacking. However, it is reasonable to assume that this subjacent tissue is granulation tissue and that in the course of time the necrotic eschars will be sloughed, as they were with the patient.

After two weeks the eschars caused by AgNO₃ were ready to separate, whereas the CaCl₂ eschars were still firmly embedded in the granulation tissue and showed no sign of sloughing.

From this study the empirical conclusions may be drawn that strong solutions of calcium and chloride ions will produce superficial necrotic lesions in the flank skin of a rabbit. The experiments do not differentiate between direct action and an osmotic action; the series of experiments described below were designed to provide such differentiation.

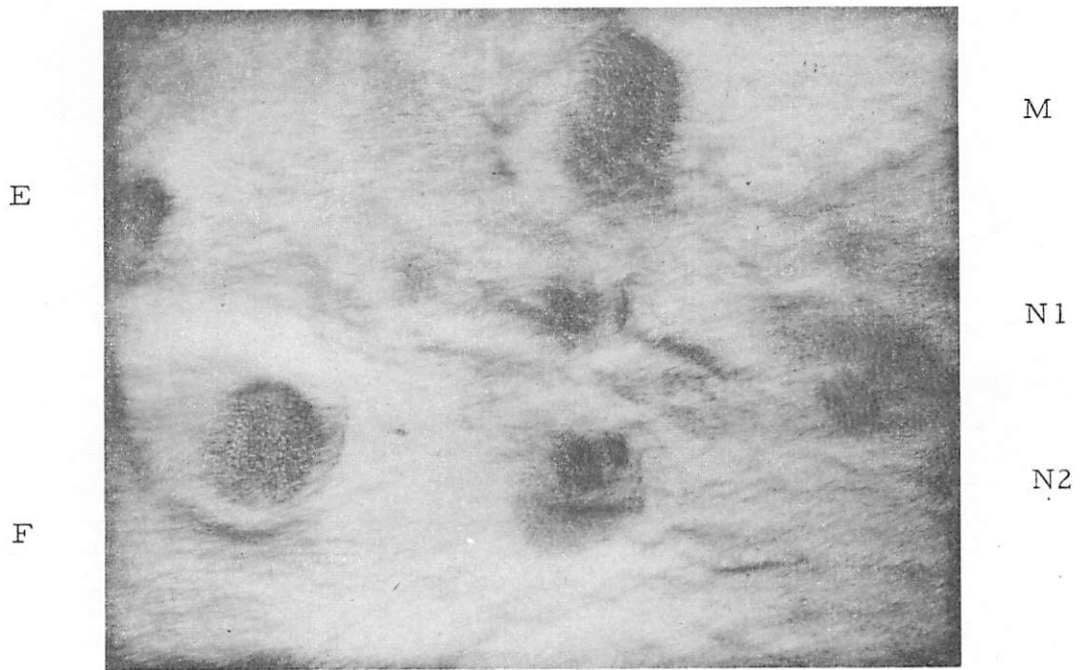


Fig. 1. Effects of subcutaneous injections.

E: first series, CaCl_2 , 5%, one week

F: first series, CaCl_2 , 10%, one week.

M: CaGlu , saturated solution, first series, one week.

N1, N2: first series, AgNO_3 , 1%, one week. The different character of these lesions is seen. They are small and have a very dark center; there is a narrow white band and a thin ring of erythema. This type should be compared with the CaGlu and CaCl_2 lesions seen elsewhere in the picture.

Theoretical Basis for Experiment

The osmotic pressure of mammalian body fluids is the same as that of a 0.15 molar solution of sodium chloride; the two solutions are isotonic. One osmole is the osmotic pressure (OP) exerted by one gram-mole of an ion. Thus, in a molar solution of NaCl, the OP due to the Na⁺ ion is one osmole, and the total osmolarity of the solution is 2 osmoles. A 0.15 M solution of NaCl has an osmolarity of $0.15 \times 2 = 0.3$ osmoles. The osmolarity of body-fluids is therefore 0.3 osmoles or 300 milliosmoles.

The relationship between osmolarity and molarity may be expressed as follows:

$$\text{Milliosmoles} = \frac{\text{Molarity} \times n}{1000},$$

where n is the number of particles or ions in a "molecule" of the salt; e.g., for NaCl AgNO₃ KI, $n = 2$; for CaCl₂ MgCl₂, $n = 3$; for Al₂(SO₄)₃, $n = 5$.

Hence, from a series of solutions with the same osmolarity it should be possible to compare the direct effects of the individual ions and exclude the effects of osmotic pressure.

Method

A series of solutions of salts was prepared with an osmolarity of 2400 milliosmoles, i.e., 8 times isotonic. The concentrations necessary for the various ions were calculated from the relationship given above. These solutions were then doubly diluted four times in

1-ml aliquots. Thus, a series of solutions with graded osmolarity was produced: 2400, (8I); 1200, (4I); 600, (2I); 300, (I); 150, (0.5I) milliosmoles. (The figures in parentheses are comparative with regard to isotonicity; 2I = twice isotonic.)

The solutions tested were as follows:

			%
1	NaCl: Milliosmoles 2400	8I	7.04
2	1200	4I	
3	600	2I	
4	300	I	0.88
5	150	0.5I	
6	CaCl ₂ : 2400	8I	8.88
7	1200	4I	
8	600	2I	
9	300	I	1.1
10	150	0.5I	
11	CaGlu: 1200	4I	17.2
12	600	2I	
13	300	I	4.3
14	150	0.5I	
15	AgNO ₃ : 2400	8I	20.4
16	1200	4I	
17	600	2I	
18	300	I	2.55
19	150	0.5I	

The isotonic solution of NaCl (4) acted as a control.

As in the preceding experiment two 0.1-ml aliquots of each solution were injected into a rabbit.

Results

NaCl Only the 8I solution produced any reaction, a small 3-mm lump in the skin. There was no discoloration and no interference with hair growth. This lump regressed in 6 days.

CaGlu The 2I and 4I solutions both produced subcutaneous lumps that lasted for 8 days but no necrosis. There was no evidence of gross necrosis, although there was some erythema.

CaCl₂ (after 24 hr; Fig. 2)

- 0.5I: a small 1.5-mm-diam. discolored area, bluish hue
- I: similar small areas discolored but not raised
- 2I: defined dark areas 3 mm in diam., somewhat hard, hair growth reduced
- 4I: large lesion, 7 mm, pale center, dark periphery, hair growth stopped
- 8I: as above, wider areas (15 mm)

In 6 days these areas progressed towards the lesions obtained in the preceding experiment: raised dark necrotic lesions, with the size relations as listed above maintained. In 8 days, the 2I solutions lesions had become slightly necrotic, whereas the I lesions were raised and erythematous.

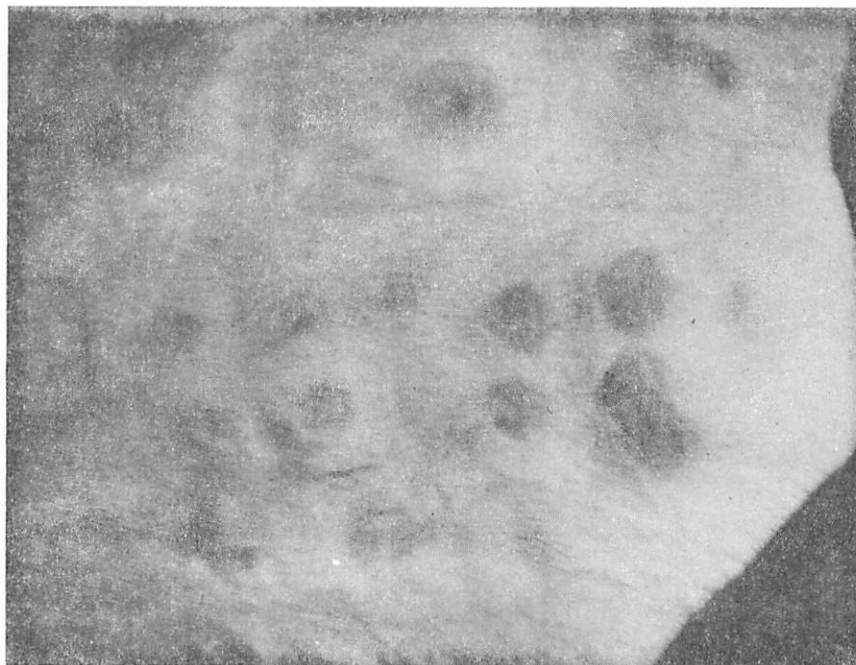AgNO₃

- 0.5I: gray center, pale periphery, erythema, 3 mm diam.
- I: gray-blue center, pale periphery, erythema, 3 mm diam. (Fig. 3)

X U V

Z

Y



M N P R S

Fig. 2. CaCl_2 series.

MNPRS: second series, CaCl_2 osmolarity series M = 0.5I, . . . , S = 8I, etc. Two lesions for each sample (three samples for 2I). The site of all the lesions may be seen; even the 0.5I injection has produced a visible inhibition of hair growth. The gradation of the lesions is well seen; the 8I lesion is well advanced after 48 hours (when the pictures were taken).

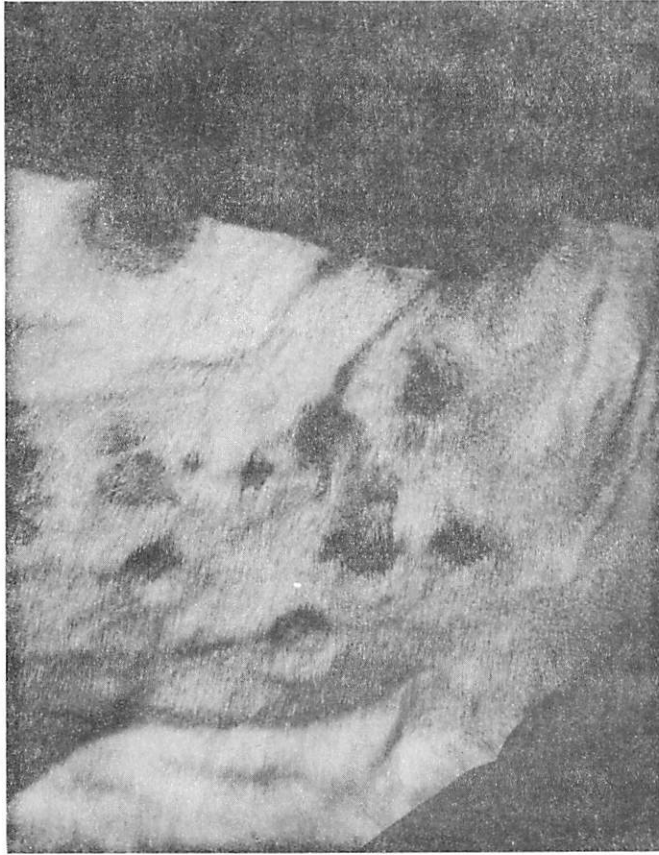Z, Y: first series lesions caused by CaGlu saturated solution after one week. The similarity to the CaCl_2 lesions may be seen.

X: first series, CaCl_2 , 5%, one week.

U, V: second series, lesions caused by 0.5I AgNO_3 . The brown coloration due to precipitated silver ions may be seen (48 hr).

G

H



I

J

K

L

Fig. 3. AgNO_3 series.

G: first series, 10% CaCl_2 , one week.

H, I, J, K, L: injection series of AgNO_3 . H = 0.5I, . . . , L = 8I, etc. These pictures taken after 48 hr. show the small difference in the size of the 0.5I lesions (H) and the 8I lesions (L). This result should be compared with the situation found with CaCl_2 lesions, where the severity is proportional to the osmolarity. The different character of the lesions can also be seen here, but that is better shown in Fig. 1.

2I: as above 3 mm diam.

4I: " " 5 " "

8I: " " 8 " "

These lesions progressed to lesions similar to those found in the previous experiment. They developed a very dark (almost black) color but the size of the lesions showed no great relation to isotonicity; the 0.5I lesion was 2 mm in diameter, whereas the 8I was only 5 mm in diameter. These results should be compared with the gradation of the CaCl_2 lesions in this series.

Discussion

Necrosis caused by CaCl_2 has been reported in several references. Nielsen (1) states that an extravenuous injection of 10 ml of a 5% solution in the cubital fossa (anterior aspect of the elbow), which was given accidentally, produced serious effects. The forearm muscles degenerated, nail growth ceased, the small muscles of the hand were paralyzed, and the resulting pain was so great that morphine had to be given for such a long period of time that the patient became addicted to the narcotic.

Urbach (2) issues a warning about the effects of inadvertent extravenuous injections of CaCl_2 solutions. He states that a painful necrosis may result and that consequently a solution of CaGlu is to be preferred for intravenous injection. This solution must always be employed for intramuscular use; CaGlu is recommended as an alternate source of calcium.

Sax (3) lists CaCl_2 as a lachrymatory agent and a possible cause of conjunctivitis.

Seelig (4) reports a case of a girl with a sloughing leg ulcer that took 8 weeks to heal and was caused by an extravenuous injection of CaCl_2 . Further experiments on guineapigs demonstrated the necrotic action of solutions stronger than 2%. In the present experiments with the rabbit, necrosis was found to occur at concentrations of less than 2%. The CaCl_2 lesions were raised and erythematous, and it seems likely that they would progress to the typical necrotic lesions seen with the stronger solutions.

Bullock and Cramer (5) found that injections of clostridial bacteria known to be capable of producing gas gangrene in rats often resulted in no apparent infection. However, if CaCl_2 was injected simultaneously, the disease process became manifest. The site of injection of the salt seemed to be the controlling factor. When the salt was injected intramuscularly and the bacteria by another route (e. g., intravenously), the gas gangrene occurred at the site of the salt injection.

No reference to necrosis caused by silver or by silver ions was found. The only condition of any interest due to silver is argyria in which ingested silver becomes deposited subcutaneously and gives the skin a blue hue.

The cutaneous prick test indicated that CaCl_2 had the edge over the other solutions in irritative properties. Whether this result was due to the higher pH or to intrinsic properties of the salt was not

clear. Whatever the reason for the higher irritative index, CaCl_2 appears to be involved.

The bentonite tests showed no reaction to the rabbit's skin. This finding may reflect differences between the skins or may emphasize the individuality of the patient's skin and the unique character of his lesions.

The series of subcutaneous injections produced three effects: a non-necrotic lump that resolved with time or stayed as a "simple lump," viz., isotonic series, CaGlu, and the more dramatic and obvious necrotic skin lesions caused by CaCl_2 and AgNO_3 . As mentioned previously, these lesions are different in extent, coloring, relation to osmolarity, and the time needed to resolve. Regarding osmolarity, CaCl_2 would appear to be related to it, but since equitonic solutions of NaCl do not produce necrosis, the tissue damage would seem to be a direct action of the salt, the increased necrosis being due to more CaCl_2 rather than to an increased osmotic action. Since CaGlu in equitonic solution does not produce lesions, the calcium ion on its own would appear to be cleared; but the chloride ion (in NaCl) produces no necrosis, so that it must be concluded that it requires a combination of the two ions to produce damage. An alternative explanation could be the presence in the CaCl_2 of impurities, e. g., a small amount of calcium oxide in the salt could have a caustic action and also push up the pH.

The necrosis produced by AgNO_3 was more localized than the CaCl_2 lesions and could be explained by immediate precipitation of the

silver ion as the chloride on coming into contact with the chloride ions of the body fluids. Hence, diffusion of the ions would be halted. The actual cause of the necrosis is not clear; it may be due to denaturation of the surrounding proteins or perhaps to a physical action of the precipitated silver, which reduces fairly rapidly to the metallic state if the darkening of the injection site can be taken as evidence.

Dr. P. E. Kellaway (6) at Baylor University in Houston has seen three pairs of lesions similar to those reported by Giffin, but Kellaway reports positive patch tests with bentonite paste. He believes that the preparation of the subject, cleaning of the skin, etc., and the presence of glycerine in the paste, render the skin sensitive to a direct action of CaCl_2 .

Giffin's patient showed no sensitivity to the bentonite paste and the sloughed eschars upon analysis were found to have a silver content of 0.14 and 0.16% by two different techniques. Thus there appear to be differences in the lesions, so that it cannot be assumed that the lesions in the cases described by Giffin and by Kellaway are indeed caused by the same mechanisms. It is in fact tempting to take the view that the lesions are caused by different mechanisms. Thus, since Kellaway's cases were patch-positive to bentonite, they could have been caused by CaCl_2 ; and since silver was found in Giffin's lesions, they could have been due to silver and be like the AgNO_3 lesions in the rabbit. We hasten to add that this view is not really tenable on the present evidence alone. To clarify the position it would be necessary to reexamine the patient, i. e., the 13-month-old child.

Thus, with regard to this child's lesions it is possible that the necrosis was due to calcium chloride or to some impurity in the salt; calcium oxide has been mentioned. It is possible that it was silver iontophoresis. In either case, the means by which silver became incorporated in the sloughed eschars remains to be determined.

REFERENCES

1. J. M. Nielsen, A Textbook of Clinical Neurology, 3rd ed., New York, Paul B. Hoeber, p. 674, 1951.
2. E. Urbach and P. M. Gottlieb, Allergy, New York, Grune and Stratton Publishing Co., p. 277, 1943.
3. N. K. Sax, Handbook of Dangerous Materials, New York, Reinhold Publishing Corp., p. 74, 1951.
4. J. Seelig, J. A. M. A., 84, 1413, 1925.
5. W. E. Bullock and W. Cramer, Proc. Royal Soc., 90(B), 513, 1919.
6. P. E. Kellaway, personal communication.